



**PRESENTAZIONE di**

**ACLAND'S VIDEO ATLAS OF  
HUMAN ANATOMY®**

Enrico Pardini - Customer Success Specialist  
3 maggio 2024



UNIVERSITÀ  
DEGLI STUDI  
DI MILANO



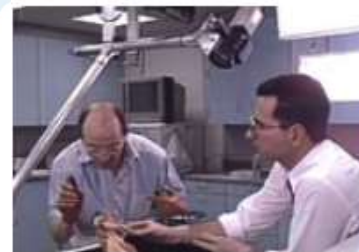**Wolters Kluwer**

# Cos'è Acland's Video Atlas of Human Anatomy?


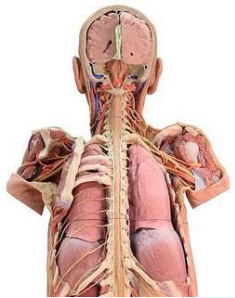
- Sviluppato e narrato dal Dr. Robert (Bob) Acland e dal suo team presso la School of Medicine dell'Università di Louisville.
- 5 Volumi con più di 300 video di macro anatomia rotazionale in 3D con veri campioni da cadavere, accompagnati da una narrazione chiara e strutture etichettate per rafforzare l'apprendimento e la revisione.
- È una piattaforma basata sui browser web che può essere visualizzata sui computer. L'interfaccia è ottimizzata per iPad e altri tablet, nonché smartphone.
- I video mostrano strutture in movimento - muscoli, tendini e articolazioni - che eseguono i movimenti naturali in vita.
- Quiz interattivi per aiutarti a valutare la padronanza dell'anatomia.
- La piattaforma è disponibile in inglese e spagnolo.
- **NOVITA': sono ora disponibili i SOTTOTITOLI IN ITALIANO**
- La piattaforma supporta più opzioni di accesso e autenticazione.

ULTERIORI INFORMAZIONI e LA STORIA DEL PROGETTO DI ACLAND:

<https://aclandanatomy.com/public/about.aspx>



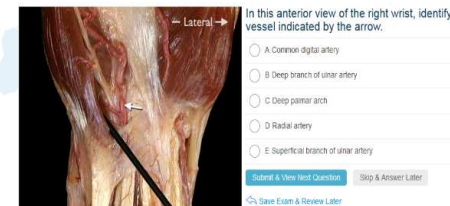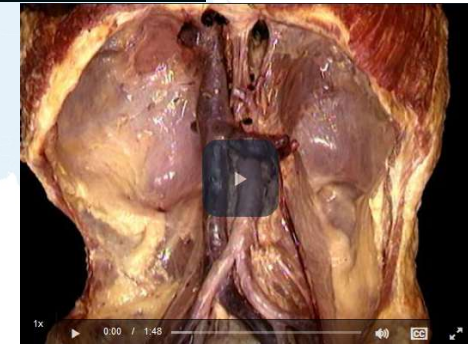
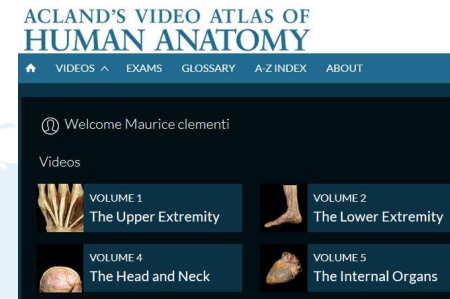# Per chi è questo prodotto?



- **Studenti di medicina e odontoiatria.** Ottima introduzione per coloro che studiano nel primo anno. Per quegli studenti che non hanno accesso alle strutture di dissezione, il Video Atlas offre un apprezzamento del vero corpo umano e una comprensione diretta della meccanica dell'anatomia funzionale.
- **Praticanti di medicina.** Praticanti chirurghi e medici apprezzano il Video Atlas come un modo rapido per rinnovare le conoscenze anatomiche e per aiutare i loro pazienti a comprendere una patologia, una lesione o una procedura.
- **Studenti nelle professioni sanitarie.** Il video Atlas è ampiamente utilizzato da studenti e insegnanti in infermieristica, terapia fisica e occupazionale, kinesiologia e massoterapia.
- **Studenti universitari.** Il video Atlas è utilizzato in molte classi di anatomia universitarie. I video possono essere compresi senza alcuna conoscenza preliminare di anatomia.






# A cosa serve?

- Acland offre una risorsa multimediale che funge da simulatore di anatomia e aiuta gli studenti a testare le proprie conoscenze.
- Fornisci agli studenti contenuti di anatomia di base intuitivi e interattivi con oltre 300 video narrati dal più celebre docente di anatomia del mondo.
- Acland presenta esemplari magistralmente sezionati, ruotati di 360 gradi. Non sono stati utilizzati fluidi per imbalsamazione.
- Per gli studenti che non hanno accesso ai laboratori di dissezione, Acland offre l'anatomia della vita reale.
- Consentire agli studenti una visione indipendente e frequente per la revisione, l'autovalutazione e la preparazione pratica all'esame.








# 5 volumi di Acland









The screenshot displays the user interface of Acland's Video Atlas of Human Anatomy. On the left, a sidebar lists five volumes, each with a representative anatomical image: Volume 1 (The Upper Extremity) shows hand bones; Volume 2 (The Lower Extremity) shows a foot; Volume 3 (The Trunk) shows a ribcage and spine; Volume 4 (The Head and Neck) shows a skull; and Volume 5 (The Internal Organs) shows a heart. The main content area on the right features a dark blue header with a yellow flag icon and the text 'Take an Exam on The Upper Extremity'. Below this, three sections are listed with white plus signs to their left, indicating they are expandable: 'The Shoulder', 'The Arm and Forearm', and 'The Hand'.

 <p>VOLUME 1 The Upper Extremity</p>	 <p>VOLUME 2 The Lower Extremity</p>	 <p>VOLUME 3 The Trunk</p>	 <p>VOLUME 4 The Head and Neck</p>	 <p>VOLUME 5 The Internal Organs</p>
<p>Take an Exam on The Upper Extremity</p>				
<p>+ The Shoulder</p>				
<p>+ The Arm and Forearm</p>				
<p>+ The Hand</p>				

# 5 volumi di Acland

	VOLUME 1 The Upper Extremity
	VOLUME 2 The Lower Extremity
	VOLUME 3 The Trunk
	VOLUME 4 The Head and Neck
	VOLUME 5 The Internal Organs

Take an Exam on The Upper Extremity			
The Shoulder			
	1.1.1 Introduction to the shoulder region (0:30)		1.1.9 Latissimus dorsi, pectoralis major and deltoid muscles (2:48)
	1.1.2 The clavicle and scapula (4:11)	REVIEW	1.1.10 Review of shoulder muscles (1:15)
	1.1.3 Movements of the clavicle and scapula (0:59)		1.1.11 Landmark structures for nerves and blood vessels (2:29)
	1.1.4 The shoulder joint and its movements (1:43)		1.1.12 Veins of the shoulder region (3:09)
REVIEW	1.1.5 Review of bones, joints, and ligaments of the shoulder (1:17)		1.1.13 Arteries of the shoulder region (2:35)

# Email e sottotitoli (ORA ANCHE IN ITALIANO)


Volume 1: The Upper Extremity > The Shoulder

TRANSCRIPT EMAIL

## 1.1.9 Latissimus dorsi, pectoralis major and deltoid muscles

JUMP TO

- Axilla
- Pectoralis major muscle
- Latissimus dorsi muscle
- Deltoid muscle



Il grande pettorale è un potente adduttore dell'omero.

0:52 / 2:47

Up Next 1.1.10 Review of shoulder muscles

See Also [axilla](#) | [deltoid muscle](#) | [latissimus dorsi muscle](#) | [pectoralis major muscle](#)

Previous Video Next Video

# Email e sottotitoli


Volume 1: The Upper Extremity > The Shoulder

TRANSCRIPT EMAIL

## 1.1.9 Latissimus dorsi, pectoralis major and deltoid muscles

JUMP TO

- Axilla
- Pectoralis major muscle
- Latissimus dorsi muscle
- Deltoid muscle



pe  
m  
- pectoral  
front, and

Email a link to this video

We will email a link to your recipient(s) that is accessible for the next 5 days (and can be clicked on 10 times maximum).

Recipient's Email:

Limited to 5 recipients.  
Separate addresses with commas.

Message (optional):

Submit Cancel



# Trascrizioni PDF da scaricare

Volume 1: The Upper Extremity > The Shoulder

TRANSCRIPT EMAIL

## 1.1.9 Latissimus dorsi, pectoralis major and deltoid muscles

JUMP TO

- Axilla
- Pectoralis major muscle
- Latissimus dorsi muscle
- Deltoid muscle

**1.1.9**  
Latissimus dorsi, pectoralis major and deltoid muscles  
(2:48)

Now we'll complete our picture by looking at three big external muscles: pectoralis major, latissimus dorsi, and deltoid.

Of these, the first two have much in common - pectoralis major on the front, and latissimus dorsi on the back. These two are alike, in that they both pass directly from the trunk to the humerus, bypassing the scapula. Between them they define the posterior and anterior walls of the axilla.

Pectoralis major arises from the medial third of the clavicle, from the front of the sternum, and from the front of the first six costal cartilages. It's inserted here, on the anterior edge of the bicipital groove. Pectoralis major is a powerful adductor of the humerus. When its adducting effect is held in check by other muscles, it also produces internal rotation.

Latissimus dorsi has a very wide origin. It starts here, under the tail end of trapezius, at T7, and goes all the way down to the sacrum, and out onto the posterior iliac crest. It also has some fibers arising from the lower four ribs, and occasionally from the tip of the scapula.

Up Next: 1.1.10 Review of shoulder muscles

# Ricerca per parole chiave di video clip

The screenshot displays a website interface with a search bar and a list of search results. The search bar contains the text "knee meniscus". The search results list includes:

- 2.2.2 Cartilages and cruciate ligaments of the **knee** joint (3:48)  
fibrocartilage. They're shaped a little differently, the lateral one is almost a circle, the medial one is more C-shaped. In cross section, each **meniscus** is thick at the outer edge and thin at the inner edge. The two ends of each **meniscus** are attached to the inter-articular area of the tibia, the medial ones ...  
Tags: fibrocartilages, capsules, cartilage, collateral ligaments, femur, knee joint, tibia, **knee meniscus**, mobility, lateral meniscus, cruciate ligaments
- 2.2.4 Review of bones and ligaments of the **knee** joint (1:37)  
patella. Here's the medial **meniscus**, the lateral **meniscus**, the anterior cruciate, and posterior cruciate ligaments. The fibular collateral ligament, the tibial collateral ligament, the quadriceps tendon, the patellar ligament, and the joint capsule. ...  
Tags: **knee** joint, ligaments, motion of knee

The search bar and the search results list are highlighted with a red border. The search bar contains the text "knee". The search results list includes "knee joint", "knee region", "knee flexion", "knee joint capsule", "knee joint extensor", and "knee meniscus".

# QUIZ

VIDEOS ^

EXAMS

GLOSSARY

A-Z INDEX

ABOUT

Search...

## Exams

Test yourself on any AclandAnatomy.com volume to which you have a subscription.

VOLUMES		LAST SCORE
Volume 1: The Upper Extremity		<a href="#">52 Questions</a>
Volume 2: The Lower Extremity		<a href="#">68 Questions</a>
Volume 3: The Trunk		<a href="#">52 Questions</a>
Volume 4: The Head and Neck	---	--- Not Started --- <a href="#">60 Questions</a>
Volume 5: The Internal Organs	---	--- Not Started --- <a href="#">70 Questions</a>

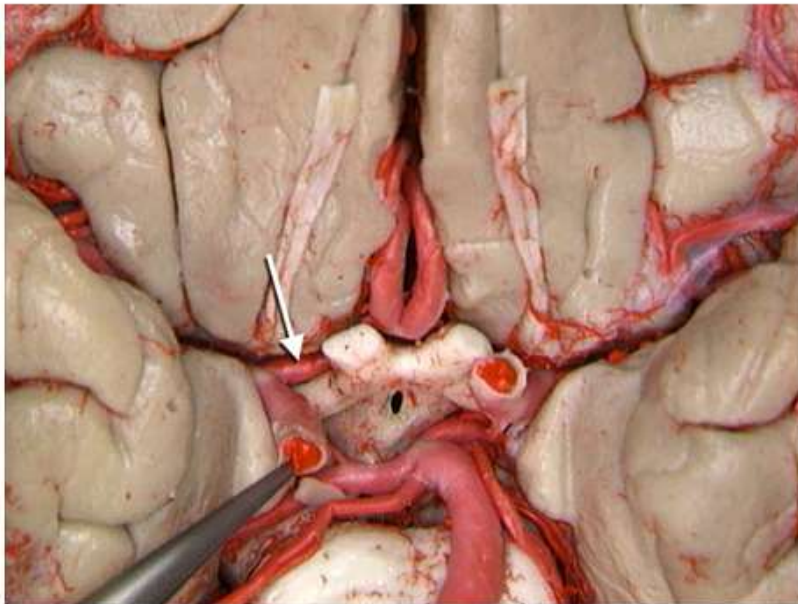
# QUIZ

## Volume 4: The Head and Neck

[Save Exam & Review Later](#)



0 Incorrect | 0 Correct | 60 Unanswered



Identify the structure indicated.

- A Anterior cerebral artery
- B Internal carotid artery
- C Middle cerebral artery
- D Posterior cerebral artery
- E Posterior communicating artery

[Submit & View Next Question](#)

[Skip & Answer Later](#)

[Save Exam & Review Later](#)

# Glossario e indice A-Z

Home VIDEOS ^ EXAMS **GLOSSARY** A-Z INDEX ABOUT

## Glossary

Many anatomic structures are still known by names given when Greek, Arabic and Latin were languages. Most anatomic names, so these interesting links with the past remain in service.

type to filter  Jump to: [A](#) [B](#) [C](#) [D](#) [E](#) [F](#) [G](#) [H](#) [I](#) [J](#) [K](#) [L](#) [M](#) [N](#) [O](#)

A		
Abduct	LATIN	<i>ab, away + ducere, pull.</i>
Acetabulum	LATIN	<i>acteum, vinegar + abrun-</i>
Adduct	LATIN	<i>ad, towards + ducere, pu</i>
Adrenal	LATIN	<i>ad, toward + ren, kidney</i>
Ala (alar)	LATIN	<i>ala, wing.</i>

Home VIDEOS ^ EXAMS GLOSSARY **A-Z INDEX**

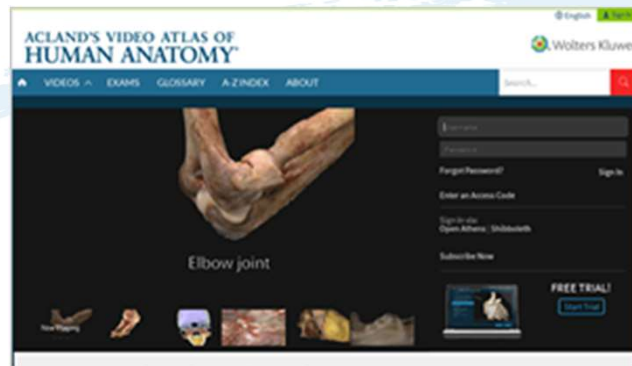
## A-Z INDEX

type to filter  JUMP TO: # [A](#) [B](#) [C](#)

A

- [abdomen](#)
- [abdominal arteries](#)
- [abdominal cavity](#)
- [abdominal muscles](#)
- [abdominal veins](#)
- [abducent nerve](#)
- [abductor digiti minimi muscle](#)

# Video e manuale per l'utente



Il video-tutorial in Italiano



Il manuale PDF in Inglese

Videos of Volume 1: The Upper Extremity	
<b>The Shoulder</b>	
1.1.1	Introduction to the shoulder region
1.1.2	The clavicle and scapula
1.1.3	Movements of the clavicle and scapula
1.1.4	The shoulder joint and its movements
1.1.5	Review of bones, joints, and ligaments of the shoulder
1.1.6	Introduction to shoulder muscles
1.1.7	Muscles passing from the scapula to the humerus
1.1.8	Muscles passing from the trunk to the scapula
1.1.9	Latissimus dorsi, pectoralis major and deltoid muscles
1.1.10	Review of shoulder muscles
1.1.11	Landmark structures for nerves and blood vessels
1.1.12	Veins of the shoulder region
1.1.13	Arteries of the shoulder region
1.1.14	Nerves of the shoulder region: the brachial plexus
1.1.15	Review of blood vessels and nerves of the shoulder region
<b>The Arm and Forearm</b>	
1.2.1	Introduction to the arm and forearm
1.2.2	Bones of the arm and forearm
1.2.3	The elbow joint
1.2.4	The distal radio-ulnar joint
1.2.5	The wrist joint
1.2.6	Review of bones, joints, and ligaments of the arm and forearm
1.2.7	Muscles that move the elbow
1.2.8	Muscles that rotate the forearm
1.2.9	Muscles that move the wrist
1.2.10	Review and overview of muscles of the arm and shoulder
1.2.11	Arteries and veins of the arm
1.2.12	Nerves of the arm
1.2.13	Review of blood vessels and nerves of the arm and forearm

Le URL dei singoli videoclip

# Centro Risorse Ovid in Italiano



## Video di Formazione

Le opzioni di formazione e aiuto possono rendere l'uso dei prodotti Ovid più semplice ed efficiente.

[Video](#)



## Documentazione di supporto

Trova domande frequenti, guide di riferimento rapido, schede prodotto e altro ancora?

[Documentazione](#)



## Contattaci

Per domande o domande più difficili, consulta la nostra Knowledge Community o semplicemente inviaci un'email direttamente.

[Contatti](#)



Grazie!

Per chiarimenti e ulteriori  
informazioni potete contattarci

[enrico.pardini@wolterskluwer.com](mailto:enrico.pardini@wolterskluwer.com)



Wolters Kluwer